

## STUDY OF MANDIBULAR NECROSIS DUE TO BISPHOSPHONATES *versus* HEALTHY BONE BY SCANNING ELECTRON MICROSCOPY AND X-RAY ENERGY DISPERSIVE SPECTROMETRY

M.V. García Garduño<sup>a\*</sup>, P. Dettmer Mendoza<sup>b</sup>, A. Morán Reyes<sup>a</sup>, J. Ramírez<sup>c</sup>, J. Reyes Gasga<sup>d</sup>

<sup>a</sup>Facultad de Odontología, DEPI, Universidad Nacional Autónoma de México, México DF.

<sup>b</sup>FES Iztacala, Universidad Nacional Autónoma de México, México DF.

<sup>c</sup>ISSSTE, Hospital "1° de Octubre", México DF.

<sup>d</sup>Instituto de Física, Universidad Nacional Autónoma de México, México DF.

\*Autor de Correspondencia: [marvicgg@servidor.unam.mx](mailto:marvicgg@servidor.unam.mx), Phone 01(55)56225567, Fax 01(55)56225009

Recibido: Octubre 2009. Aprobado: Enero 2010.

Publicado: Enero 2010.

### ABSTRACT

The mandibular necrosis seen in cancer pathologies following chemotherapy is a subject of interest to the whole biomedical community and specially dentists, who in the face of this problem don't find the solution in any routine treatment, since mandibular necrosis is initiated by any dental treatment and goes on until the entire mandible and occasionally the maxilla is damaged. In this work try to elucidate the process originating mandibular necrosis when patients treated with bisphosphonates after chemotherapy, undergo dental treatment. Therefore, healthy bone will also be studied in order to make a comparison. Necrosed and healthy bones were obtained by donation after medical biopsy. Bone was prepared for light microscopy, scanning electron microscopy (SEM) and X-ray energy dispersive spectrometry (EDS). The comparison of the necrosed and healthy bone indicated morphological and chemical differences. The electron microscopy and chemical analysis observations supported this. We can state that in necrosis vasculature collapses as indicated by other authors, but we suggest the circulatory lack alters severely the bone remodeling mainly in the alveoli, affecting the soft tissues feedback with bone and thus all of the tissue is lost.

**Keywords:** Mandibular necrosis; bisphosphonates; healthy bone.

### ESTUDIO DE LA NECROSIS MANDIBULAR POR BIFOSFONATOS *versus* HUESO SANO MEDIANTE MICROSCOPIA DE LUZ, MICROSCOPIA ELECTRONICA DE BARRIDO Y ESPECTROMETRIA POR DISPERSION DE RAYOS X.

### RESUMEN

La necrosis mandibular se presenta en las pacientes con cáncer de mama posterior a la quimioterapia cuando son tratadas con bisfosfonatos. En estas condiciones resulta la necrosis cuando se someten al más leve tratamiento odontológico. Hasta la fecha esta patología no tiene solución y puede necrosarse también el hueso mandibular superior. Esto ha dado origen a una gran cantidad de investigaciones. El objetivo de este trabajo es dilucidar el proceso que desencadena la necrosis mandibular, para lo cual se compara el hueso necrosado con el hueso sano. El hueso necrosado se obtuvo por donación después de la biopsia y se preparó para ser estudiado por microscopía de luz, microscopía electrónica de barrido (SEM), espectrometría por dispersión de rayos X (EDS). La comparación del hueso necrosado con el hueso sano muestran diferencias morfológicas y químicas. Se puede establecer que la necrosis se presenta por colapsos vasculares. La falta de circulación altera severamente la remodelación ósea principalmente en el alveolo, afectando la retroalimentación de los tejidos suaves con el hueso y así los tejidos se pierden.

**Palabras claves:** Necrosis mandibular, bifosfonatos, hueso sano.

### INTRODUCTION

Mandibular necrosis is a very serious pathology arising in breast cancer patients when they undergo any dental treatment, such as curettage or a tooth extraction [1-3] performed after chemotherapy and bisphosphonate

treatment. The mandibular bone is irreversibly necrotized, also affecting the upper jaw bone [2, 3]. Cancer patients display changes in the metabolism of calcium, resulting in the development of osteoporosis. The treatment of choice is with bisphosphonates, since

the bony improvement in the osteoporosis patients has been reported to be from 50% to 80%.

Bisphosphonates (BFs) are chemical compounds similar to pyrophosphates, whose specific function is mediating the synthesis of hydroxyapatite, the constitutive part of the osseous mineral phase [4]. In 1865, Fleisch et al [2] observed crystal of calcium phosphates inside the pyrophosphate indicating that the growth and dissolution of these crystals were forbidden. Fleisch, Francis and Russel showed, then, that BFs worked in similar way than pyrophosphates, and that the BFs inhibited mineralization and re-absorption in animals. BFs were first used in 1897 as a detergent additive, because of their cloth softening action [4]. These compounds have two phosphonate groups linked to the same carbon atom. Trials were performed and it was noticed that they were chemical agents useful in treating hard waters. BFs were taken as substances having a great affinity for the calcium and magnesium ions present in hard water, and they actually worked to improve the quality of this type of fluid. Later, in the mid-1950's, their use in fluoride toothpastes was begun and the protective Ca Fe and Sn(PO<sub>4</sub>)<sub>2</sub> film was utilized, applied with BFs not dissolving the Ca deposits; thus, thanks to the film they form, BFs were used as a vehicle for applying fluoride [5].

Because of the calcium affinity qualities, BFs have been used in the treatment of osteoporosis, Paget's disease, bony metastases, imperfect osteogenesis, heterotrophic ossifications, and in decreasing the risk of fracture in menopausal women, although Licata [2, 6] who analyzes all these applications, warns that more thorough researches of these issues must be made.

The aim of this work is to compare necrotic mandibular bone to healthy bone, studied by Light Microscopy, Scanning Electron Microscopy (SEM) and X-ray Energy Dispersive Spectrometry (EDS). The benevolence of BFs in the treatment of osteoporosis has been considered; however, research has indicated diverse outcomes in

which untoward effects are also observed due to the treatment with these medicaments.

## MATERIALS AND METHODS

Healthy bone was obtained by means of extractions of third molars. Necrotized bone was obtained by donation after a medical biopsy. It belonged to an adult woman treated with chemotherapy and BFs, who after treatment developed mandibular necrosis. The bones were placed in physiological saline solution after the biopsy. The Carl Zeiss light microscope model Axiovert 25 was used in this step of the process. For SEM and EDS sample, a bone fragment was placed on a stub and observed and analyzed by SEM and EDS. A microscope JEOL JSM-5600 LV that has attached the NORAN-EDS equipment was used for this analysis. Because the microscope is of low vacuum, no additional treatment was needed in the samples. For X-ray diffraction analysis, the bone fragment was placed in the holder of the XRD equipment Bruker model D8-Advanced using monochromatic Cu K $\alpha$  radiation ( $\lambda = 0.154$  nm). The diffraction patterns were scanned with a step size of 0.02° (2 $\theta$ ) and 25 s counting time per step using the Bragg-Brentano geometry.

## RESULTS AND DISCUSSION

Figure 1 shows the SEM image of the healthy bone. In this image all the characteristic structures are well defined and the compact and porous bones are observed. The EDS spectrum of the healthy bone is shown in figure 2 and all the elements already reported in the bone are observed. The analysis of this EDS spectrum indicated the existence of hydroxyapatite.

Figure 3 shows the light microscopy images of necrotized bone. Note the points of damage in figure 3a and the circulatory necroses in figure 3b. The image in figure 3c shows an entirely damaged tissue.

Figure 4 shows SEM image of the necrotic bone. At difference in the healthy bone, the characteristic of the



Fig. 1. SEM image of healthy bone. The compact and porous bones are observed

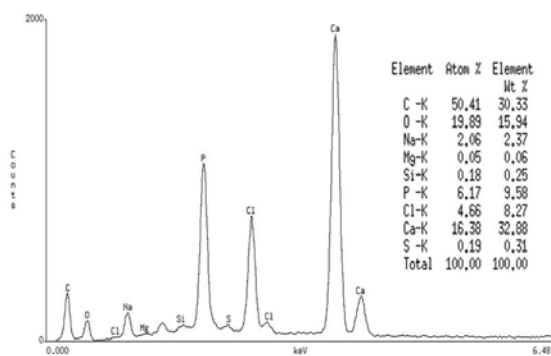


Fig. 2. EDS spectrum of the healthy bone. All the elements already reported in the bone are observed.

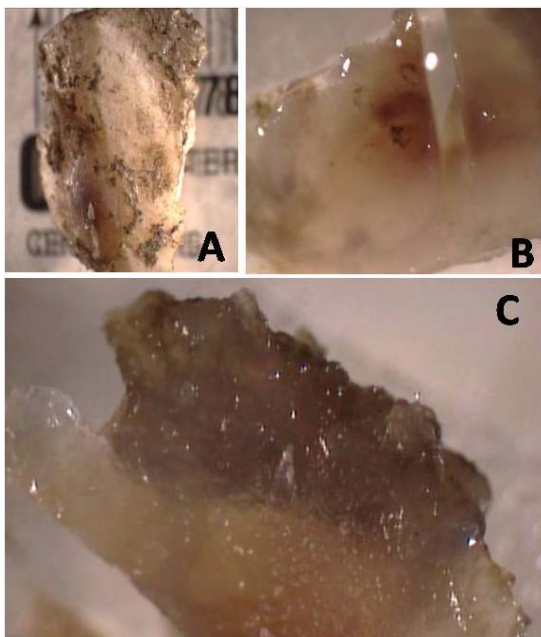


Fig. 3. Light Microscopy images of necrotized bone. Note the points of damage in (A) and the circulatory necrosis in (B). The image in (C) shows entirely damaged tissue

bone have disappeared and the image presented too much damage. Figure 5 shows the EDS spectrum of the necrotic bone and the changes are drastic. Comparing with figure 2, figure 5 shows in addition to the elements reported in the healthy bone a great increment of aluminum.

Figure 6 shows x-ray diffraction spectrum from the necrotic bone where the indicated bars correspond to hydroxyapatite. Note the amorphization of the material in this case.




Fig. 4. SEM image of the necrotic bone. The characteristic structures of a healthy bone (figure 1) have disappeared and the bone is presented too damage.

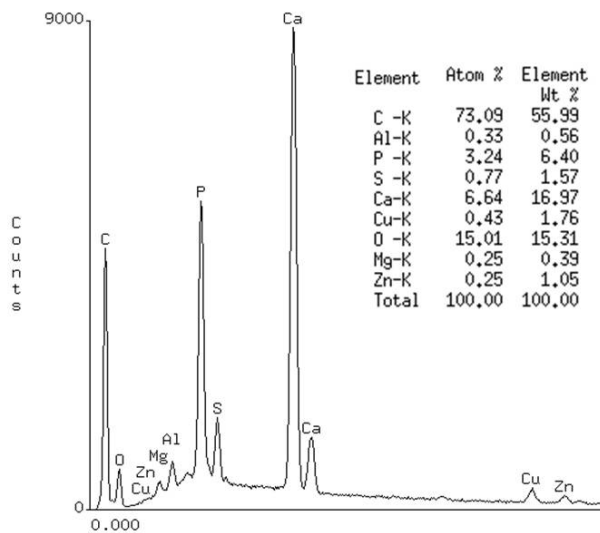


Fig. 5. EDS spectrum of the necrotic bone. In addition to the elements reported in the healthy bone (figure 2), a great increment of aluminum is observed.

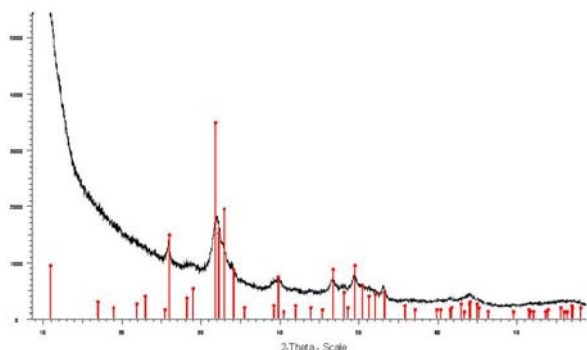


Fig. 6. X-ray spectrum of the necrotic bone. The indicated bars correspond to hydroxyapatite. Note the amorphization of the material.

Mandibular necrosis is an active process, presenting as a progressive and sustained pain which does not subside with analgesics in high doses; there is suppuration of the gingival fissure, with bone exposure; tissues change gradually with different activities, from invasion by bacteria of the genus *Staphylococcus aureus*; cyanotic necrotized tissue is observed in the soft tissues as well as in the mineralized zones [7]. Some investigations, such as the one by Nancollas, point out that the BF action disturbs the osteoclasts activities by preventing their recruitment [8]; therefore the bone loses its osseous turnover and remodeling. The experiments performed by Flesh in rats indicate that BFs given orally alter the digestive tract from the esophagus to the intestine, and the intravenous administration forms solid residues which travel through the blood increasing its viscosity.

The damage dental organs should be removed as preventing measurement for patients close to begin a BF treatment in order to reduce mandibular necrosis. In fact, every chirurgic dental procedure should be completed before any treatment with BFs. In patients under BFs treatments have to be closely supervised by dentists to not allow any light oral lesion. In case of dental removal prosthesis, the patient has to be very carefully with the lesion to avoid irritation that end in a mandibular necrosis.

It is worth to mention, however, that many authors have reported a good behavior of BFs, such as the interruption

of the osseous metastatic in bone cancer [9, 10] that avoid the progress of osteoporosis [11]. Then they have promoted the use of BFs as biomaterial [12].

The actual works of researchers is, therefore, elucidate the pros and against of the use of BFs. Taking in account that the mandibular necrosis is neither a gender, hormone nor age problem [13, 14], is almost sure that environmental pollution and individual habits are also included.

## CONCLUSIONS

We can conclude that our investigations indicate the necrosis occurs through a lack of blood supply produced by the feedback in the osseous remodeling and the loss of osteoclastic activity and, in individuals who have undergone chemotherapy, this process becomes irreversible, since as have been reported the BFs also alter the hydroxyapatite nucleation.

## ACKNOWLEDGMENTS

Authors acknowledge the technical support of Pedro Mexia, Manuel Aguilar, Samuel Tehuacanero, Jacqueline Cañetas, Carlos Magaña, Roberto Hernández, Diego Quiterio, Martha Cacho and Rosa Ma. Álvarez.

## REFERENCES

- [1] Jimenez Soriano Y, Bagan J. V. (2005) Bisphosphonates as a new cause of drug-induced jaw osteonecrosis: An update. "Med Oral Pathology Oral Cir Bucal" 10 Supp E 12:88-91.
- [2] Jaimes M, Olivera G. R., Olate S, Albergaria Barbosa J. R. (2008) "Bisphosphonate related to osteonecrosis of the jaws" Literature Review. Adv Odontoestomatol, Madrod 24:1-10
- [3] J. L. del Castillo Pardo de Vera, J. A. García de Marcos S., Arroyo Rodríguez M., Galdeano Arenas. (2007) "Osteonecrosis de los maxilares asociada al empleo de los bisfosfonatos" .Rev Esp Cir Oral y Maxilofac. 29:5, 295-308

- [4] Fleisch H, (1998) "Bisphosphonates. Mechanisms of action" *Endocr.Rev.* 19:80-100
- [5] Fleisch H., Russel, R. G., y Francis, M. D. (1969) "Diphosphonates inhibit hydroxyapatite dissolution in vitro and bone resorption in tissue culture and in vivo" *Science* 15:9, 1262-1264
- [6] Licata A. A. (2005) "Discovery, clinical development and therapeutic use of bisphosphonates". *Ann Pharmacother* 39:668-677
- [7] A. Ganguli, C. Steward, S. L. Butler, G. J. Philips, S. T. Meikle, A. W. Lloyd, M. H. Grant.(2005) "Bacterial adhesion to bisphosphonate coated hydroxyapatite". *Journal of Materials Science: Materials in Medicine* 16: 283-287
- [8] G. H. Nancollas, R. Tang, R. J. Phipps, Z. Henneman, S. Gudde, W. Wu, A. Mangood, R. G. G. Russel, F. H. Ebetino. (2006) "Novel insights in to actions of bisphosphonates on bone: Differences in interactions with hydroxyapatite" *Bone* 38:617-627.
- [9] Fleisch Herbert. (2002) "Review.Development of bisphosphonates" *Breast Cancer Res.* 4:30-34
- [10] R. Verdijk, H. R. Franke, F. Wolbers, I. Vermes. (2007) "Differential effects of bisphosphonates on breast cancer cell lines" *Cancer Letters.* 246:7: 308-312.
- [11] F. Baus, D. W. Dempster (2007) "Review. Effects of ibandronate on bone quality: preclinical studies" *Bone* 40: 265-273
- [12] Luisa Plantalech, (2007) "Tratamiento de la Osteoporosis: Novedades, Actualizaciones en Osteología", vol 3: 2
- [13] Body J. J, (2001) "Mammary Gland" *Biol. Neoplasia*, 6:417-485
- [14] Timoleòn Anguita C, Jaime Agurto P., Ivan Roa E, German Laissle C. (2006) "Osteonecrosis asociada al uso de bifosfonatos: A propósito de un caso clínico". *Rev Med Chile* 134:1161-1165.